

POPLITEAL FOSSA

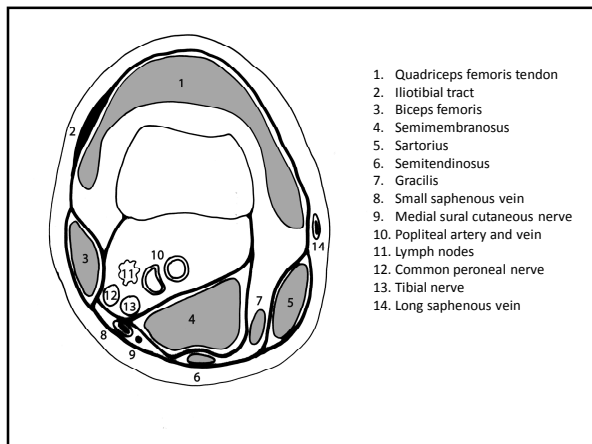
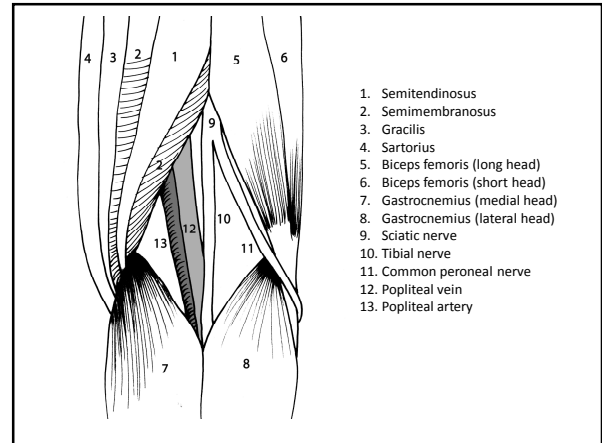
Marc Revol (2010)

Rhomboidal region

- Lateral border
 - Proximal : biceps femoris
 - Distal : lateral head of the gastrocnemius + Plantaris
- Medial border
 - Proximal : semitendinosus + semimembranosus
 - Distal : medial head of the gastrocnemius
- Anterior floor : femoral popliteal surface, popliteus, knee joint
- Posterior roof : popliteal fascia

content

- Popliteal artery and vein
- Lymph nodes
- Short saphenous vein
- Tibial nerve (and medial sural cutaneous nerve)
- Common peroneal nerve (and lateral sural cutaneous nerve)
- Posterior femoral cutaneous nerve



SOURCES

GRAY'S ANATOMY. The anatomical basis of clinical practice
Elsevier Churchill Livingstone, 39th edition, 2005 (1627 p)

Manuel de chirurgie plastique, reconstructrice et esthétique
Sauramps Médical, 2^{ème} édition, 2009 (874 p)