

FOOT

Marc Revol (2010)

Dorsal aspect

- Tibialis anterior
- Extensor hallucis longus
- Extensor digitorum longus
- Fibularis tertius
- Extensor hallucis brevis
- Extensor digitorum brevis
- Dorsalis pedis artery
- Deep peroneal nerve
- Deep dorsal fascia

Plantar aspect

Plantar fascia (or aponeurosis), intermuscular septa, and metatarsals bound 4 compartments:

- Medial compartment
- Central compartment
- Lateral compartment
- Interosseous compartment

Medial compartment contains :

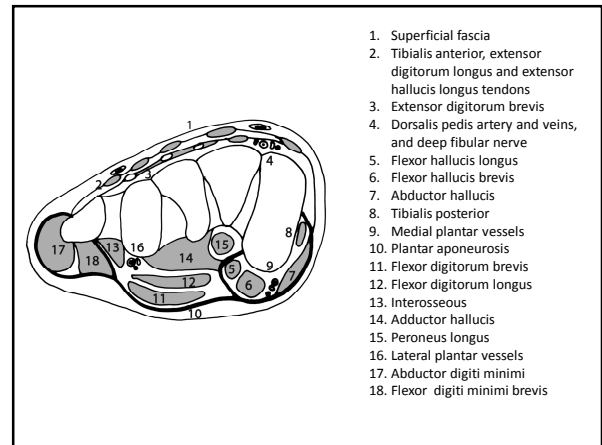
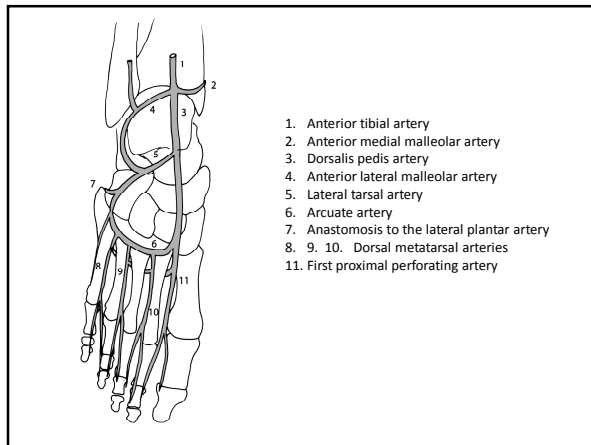
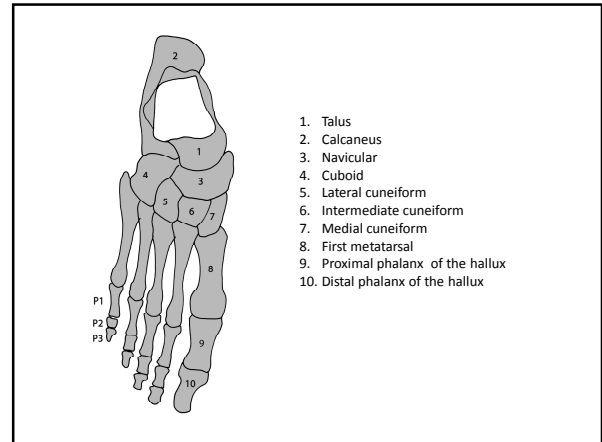
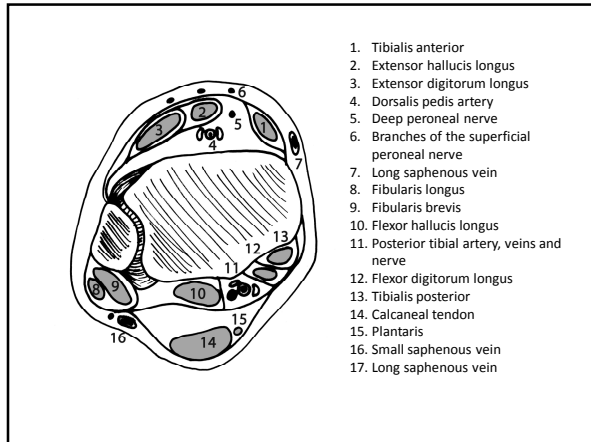
- Flexor hallucis brevis
- Flexor hallucis longus
- Abductor hallucis
- Medial plantar artery, veins and nerve

Central compartment contains :

- Flexor digitorum brevis
- Lateral plantar artery, veins, and nerve
- Flexor digitorum communis
- Lumbricals
- Quadratus plantae (flexor accessorius)
- Flexor hallucis longus
- Adductor hallucis

Lateral compartment contains :

- Abductor digiti minimi
- Flexor digiti minimi brevis
- Opponens digiti minimi



sources

GRAY'S ANATOMY. The anatomical basis of clinical practice
Elsevier Churchill Livingstone, 39th edition, 2005 (1627 p)

Manuel de chirurgie plastique, reconstructrice et esthétique
Sauramps Médical, 2^{ème} édition, 2009 (874 p)